

Marc Remacle · Hans E. Eckel · Antonio Antonelli
 Daniel Brasnu · Dominique Chevalier
 Gerhard Friedrich · Jan Olofsson · Heinrich H. Rudert
 Walter Thumfart · Marco de Vincentiis
 Thomas P. U. Wustrow

Endoscopic cordectomy. a proposal for a classification by the Working Committee, European Laryngological Society

Received: 29 December 1998 / Accepted: 2 July 1999

Abstract The European Laryngological Society is proposing a classification of different laryngeal endoscopic cordectomies in order to ensure better definitions of post-operative results. We chose to keep the word “cordectomy”

even for partial resections because it is the term most often used in the surgical literature. The classification comprises eight types of cordectomies: a subepithelial cordectomy (type I), which is resection of the epithelium; a subligamental cordectomy (type II), which is a resection of the epithelium, Reinke’s space and vocal ligament; transmuscular cordectomy (type III), which proceeds through the vocalis muscle; total cordectomy (type IV); extended cordectomy, which encompasses the contralateral vocal fold and the anterior commissure (type Va); extended cordectomy, which includes the arytenoid (type Vb); extended cordectomy, which encompasses the subglottis (type Vc); and extended cordectomy, which includes the ventricle (type Vd). Indications for performing those cordectomies may vary from surgeon to surgeon. The operations are classified according to the surgical approach used and the degree of resection in order to facilitate use of the classification in daily practice. Each surgical procedure ensures that a specimen is available for histopathological examination.

M. Remacle (✉)
 Service d’Otorhinolaryngologie et de Chirurgie cervico-faciale,
 Cliniques Universitaires de Louvain à Mont-Godinne,
 5530 Yvoir, Belgium
 e-mail: remacle@orlo.ucl.ac.be,
 Tel.: ++32 81 42 30 21, Fax: ++32 81 42 37 03

H. E. Eckel
 Hals-Nasen- und Ohrenheilkunde der Universität zu Köln,
 50924 Cologne, Germany

A. Antonelli
 Clinica ORL, Spedali Civili di Brescia, 25123 Brescia, Italy

D. Brasnu
 Service d’Otorhinolaryngologie et de Chirurgie de la face
 et du cou, Hôpital Laennec, rue de Sèvres 42, 75340 Paris, France

D. Chevalier
 Service d’Otorhinolaryngologie et de Chirurgie cervico-faciale,
 Hôpital Huriez, place de Verdun, Lille, France

G. Friedrich
 University Ear, Nose and Throat Hospital,
 Karl Franzens University, Auenbruggerplatz 20, 8036 Graz, Austria

J. Olofsson
 Department of Otolaryngology/Head and Neck Surgery,
 Haukeland University Hospital, University of Bergen,
 5021 Bergen, Norway

H. H. Rudert
 Klinik für Hals-, Nasen-, Ohrenheilkunde,
 Kopf- und Halschirurgie,
 Klinikum der Christian-Albrechts-Universität zu Kiel,
 Arnold-Heller-Strasse 14, 24105 Kiel, Germany

W. Thumfart
 Auenbruggerplatz, 20, 8036 Innsbruck, Austria

M. de Vincentiis
 Istituto Di Clinica Otorinolaringoiatrica,
 Universta degli studi di Roma “La Sapienza”,
 Viale del Policlinico, 00161 Roma, Italy

T. P. U. Wustrow
 Wittelsbacherplatz (Arco-palais) I/II, 80333 München, Germany

Key words Glottic cancer · Classifications · Endoscopic cordectomy

Introduction

Lynch [13] first introduced the technique of endoscopic cordectomy in 1920. Lillie and De Santo [12] in 1973 and Kleinsasser [10] in 1974 reported excellent results for a series of endoscopic cordectomies that were performed using cold instruments. However, it has only been since Strong’s work [24] and use of the CO₂ laser that the present technique of cordectomy began to develop.

Authors usually report very good results with regard to oncological and functional outcomes [1, 3, 6, 7, 15]. However, on reading those works, one notices that the extent of resection, which depends on the size of the lesion, is not always defined [4, 16, 20–22]. Furthermore, there is no uniformity between the classifications proposed by the various authors [3, 5, 6, 18–21]. Certain classifications

lack precision or are incomplete. We therefore thought it useful to propose a classification of the different cordectomies according to the extent of the resection.

Our proposed classification is a synthesis of the categorizations available in literature and the classifications that have been previously and separately presented by several authors of this article. The aim of our proposal is not to define or restrict therapeutic indications, but, by means of this common classification, to allow interpretation and comparison of postoperative results achieved by different centers, depending on the extent of the tumor and various surgical indications.

Classification proposal

Subepithelial cordectomy (type I)

Subepithelial cordectomy is the resection of the vocal fold epithelium, passing through the superficial layer of the lamina propria (Fig. 1 a, b). This surgical procedure spares the deeper layers and thus the vocal ligament. Subepithelial cordectomy is performed for cases of vocal fold lesions suspected of premalignant or malignant transformations. As the entire epithelium is generally affected in various degrees of severity, it is usually necessary to resect it completely. This is undertaken in order to avoid leaving in place a dysplastic or even carcinomatous area. In the rarer cases where epithelial modifications are restricted to a segment of the vocal fold, the clinically normal epithelium may be preserved.

Because subepithelial cordectomy ensures a histopathological examination of the entire epithelium of the vocal fold, the main role of this surgical procedure is diagnostic. It can also be therapeutic if histological results confirm a hyperplasia, dysplasia, or carcinoma in situ without signs of microinvasion. Indeed, by definition, these lesions are limited to the epithelium. If, on the other hand, there are signs of invasive tumor spread, a further procedure is required.

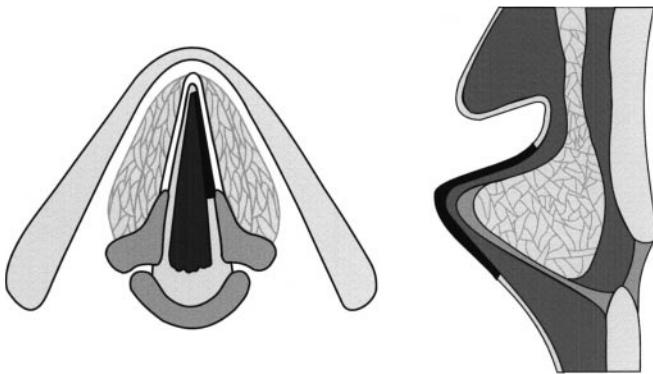


Fig. 1 a, b Subepithelial cordectomy (type I)

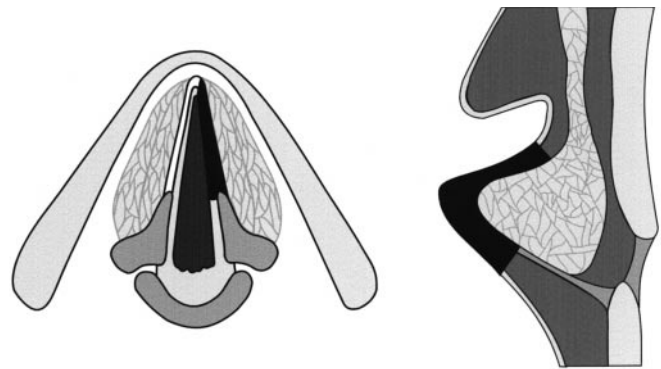


Fig. 2 a, b Subligamental cordectomy (type II)

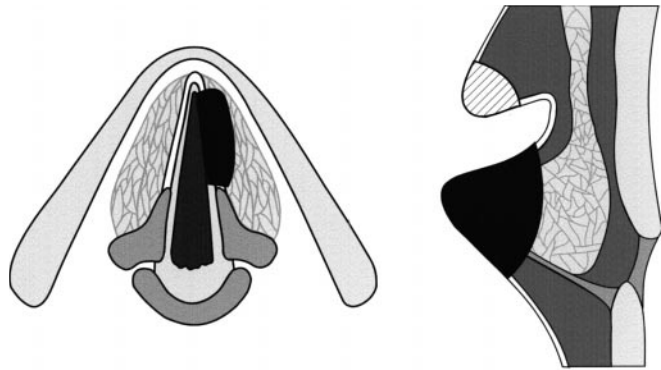


Fig. 3 a, b Transmuscular cordectomy (type III). In order to expose the entire vocal fold, partial resection of the ventricular fold may be necessary (hatched area)

Subligamental cordectomy (type II)

Subligamental cordectomy is the resection of the epithelium, Reinke's space and the vocal ligament (Fig. 2 a, b). Subligamental cordectomy is performed by cutting between the vocal ligament and the vocal muscle. The vocal muscle is preserved as much as possible. The resection may extend from the vocal process to the anterior commissure.

At a diagnostic level, this procedure is indicated for cases of severe leukoplakia when a lesion shows clinical signs of neoplastic transformation and stroboscopic examination indicates a deeper infiltration, or "vibratory silence". When palpated, this infiltration feels thickened and the mucosa cannot freely be moved over the underlying structures. At a therapeutic level, subligamental cordectomy is indicated for cases of microinvasive carcinoma or severe carcinoma-in-situ with possible microinvasion.

Transmuscular cordectomy (type III)

Transmuscular cordectomy is performed by cutting through the vocalis muscle (Fig. 3 a, b). The resection encompasses the epithelium, lamina propria, and part of the vocalis muscle. The resection may extend from the vocal process to the anterior commissure.

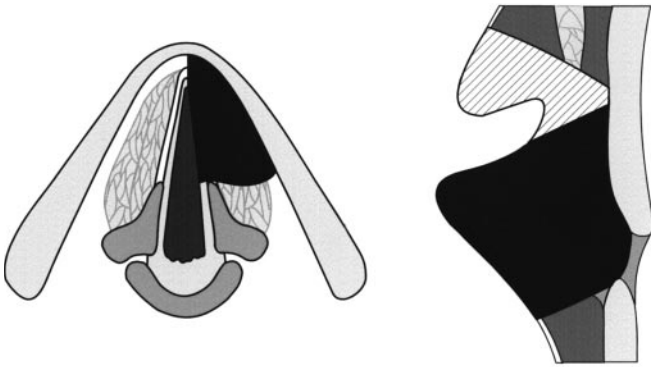


Fig. 4 a, b Total or complete cordectomy (type IV). The ipsilateral ventricular fold can be removed partially or totally to ensure complete resection of the vocal fold (hatched area)

In order to expose the entire vocal fold, partial resection of the ventricular fold may be necessary. This resection of the vestibular fold conforms with the vestibulectomy as described by Swarc and Kashima [25].

At a therapeutic level, a transmuscular cordectomy is indicated for cases of small superficial cancer of the mobile vocal fold. The technique may be indicated for cases of cancer, where cancer reaches the vocal muscle without deeply infiltrating it.

Total or complete cordectomy (type IV)

Complete cordectomy extends from the vocal process to the anterior commissure (Fig. 4 a, b). The depth of the surgical margins reaches the internal perichondrium of the thyroid ala. Sometimes the perichondrium is included with the resection. Anteriorly, the incision is made in the anterior commissure. It is important that the attachment of the vocal ligament to the thyroid cartilage is cut. Complete cordectomy is indicated for cases of T1a cancer, where cancer infiltrates the vocal fold and is diagnosed prior to surgery. The procedure, which does therefore not serve any diagnostic purpose, is purely curative.

Extension of a neoplasm may spread as far as the anterior commissure, but without involving it. At the anterior commissure, the distance between mucosa and cartilage is at maximum 2–3 mm. Although there is no internal perichondrium to resist tumoral invasion of the thyroid cartilage, Broyle's tendon may act as a barrier to the further spread of these carcinomas.

Complete cordectomy can be extended when it is necessary to remove partially or totally the ipsilateral ventricular fold in order to ensure complete resection of the vocal fold.

Extended cordectomy encompassing the contralateral vocal fold (type Va)

The resection includes the anterior commissure and, depending on the extent of the tumour, either a segment or

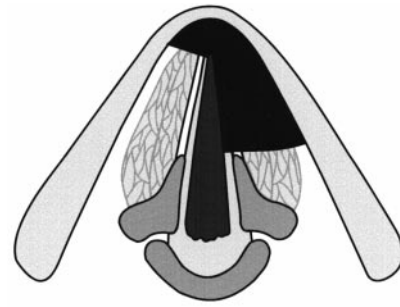


Fig. 5 Extended cordectomy encompassing the contralateral vocal fold (type Va). The extent of the resected contralateral vocal fold depends on the extent of the tumor

the entire contralateral vocal fold (Fig. 5). The resection must continue along the cartilage at the height of the anterior commissure, thereby removing Broyle's ligament. To achieve this, the incision starts above the insertion plane of the vocal folds, at the base of the epiglottic insertion, and then passes through Broyle's ligament. To achieve this extend of resection, it may be necessary to resect the petiole of the epiglottis to ensure sufficient visualization. If necessary, the incision is continued towards the subglottis. In order to ensure a good exposure of the contralateral vocal fold, resection of the contralateral ventricular fold may also be necessary. The extent of this resection may vary.

According to some surgeons [6, 16, 23], a T1b tumor involving the anterior commissure can be managed by this procedure. In this case, the resection must include the subglottic mucosa and the cricothyroid membrane [6] because cancers of the anterior commissure tend to spread towards the lymphatic vessels of the subglottic area [9]. This approach is somewhat controversial since other clinicians have found that a T1b carcinoma of the vocal fold involving the anterior commissure is not a good indication for proceeding with an endoscopic excision because resection around the anterior commissure is difficult [11, 19]. However, cordectomy encompassing the contralateral vocal fold has been recommended for cancers superficially reaching the commissure without infiltrating it, and without spreading towards the base of the epiglottis or towards the subglottis [20, 21].

Extended cordectomy encompassing the arytenoid (type Vb)

This technique is indicated for cases of vocal fold carcinoma involving posteriorly the vocal process but sparing the arytenoid (Fig. 6). The arytenoid is mobile. The cartilage is partially or totally resected and the posterior arytenoid mucosa is preserved. According to certain laryngologists, the vocal fold must be completely mobile [19]. Other clinicians have indicated that the mobility of the vocal fold may be impaired as long as the arytenoid itself remains mobile and the fixation only involves the muscular

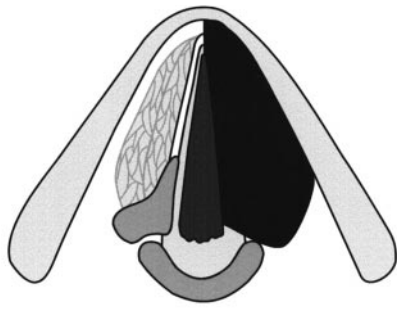


Fig. 6 Extended cordectomy encompassing the arytenoid (type Vb)

Fig. 7 Extended cordectomy encompassing the ventricular fold (type Vc). The inferior resection of the vocal fold is maximum

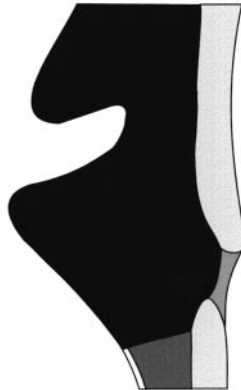
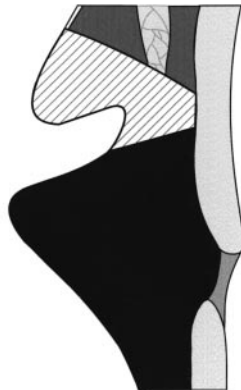
Fig. 8 Extended cordectomy encompassing the subglottis to a distance of 1 cm (type Vd)



vocal fold [6]. According to yet others, the vocal fold may even be totally fixed [22, 23].

Extended cordectomy encompassing the ventricular fold (type Vc)

According to certain schools [6, 21–23], total cordectomy can be extended to the ventricular fold (Fig. 7). This procedure is indicated for ventricular cancers or for transglottic cancers that spread from the vocal fold to the ventricle. The specimen encompasses the ventricular fold and Morgani's ventricle.

Extended cordectomy encompassing the subglottis (type Vd)

If necessary, cord resection can be continued as deep as 1 cm under the glottis in order to expose the cricoid cartilage (Fig. 8). However, this is a contraindication according to certain surgeons [19].

In selected cases, the extended cordectomies are suitable for T2 carcinoma [6, 21–23].

Discussion

The aim of this classification is not to define or set indications. In fact, and as previously reported by the coauthors of this article, the indications vary. However, we believe that a common classification of cordectomies is necessary in order to understand and compare postoperative results following different types of cordectomies that are based on each surgeon's own indications. Furthermore, this system serves another purpose: to improve the teaching and training of inexperienced laryngologists. We believe that non-standardized surgery, which requires years of training to understand its limits, offers little reproducibility to the majority of laryngologists. All reproducible techniques have guidelines.

We restricted our description to the surgical margins of the various cordectomies. We did not describe the different school-dependent surgical techniques, as they vary. Thus, certain surgeons [21, 22] incise through a tumor in order to expose its macroscopic limits and to facilitate surgery, while others [6, 19] do not cut tumor in order to obtain an intact specimen.

We avoided confusing techniques and instruments. Indeed, this is a classification of endoscopic cordectomies and not of laser-assisted cordectomies. The proposed classification remains valid whatever the instrument: microscissors, electrocautery, CO₂ laser, YAG laser or diode laser. The different types of endoscopic cordectomies may also be compared to the techniques of cordectomy and partial laryngectomy performed via an external approach.

To describe more extensive procedures, terms may have to be combined. For example, a resection of a transglottic tumor with infiltration of the anterior commissure and the arytenoid may be operated on with a type V a,b,c resection. At a technical level, however, the endoscopic cordectomy is a resection and not a vaporization [14]. Whatever the extent of the resection, a specimen is always available for histopathological examination.

Each type of cordectomy in the present classification is defined by name. Definition via a name is more comprehensible for laryngologists still unfamiliar with the proposed classification. The nominal definitions are, however, accompanied by a numerical classification, which is shorter to enumerate and therefore more practical in everyday practice. Obviously, this definition can only stand out if the classification becomes a reference such as the TNM classification. Until that time, the present classi-

fication avoids the risk of confusion with other existing personal classifications [5, 6, 18–21].

Our proposed classification results from an agreement among the different authors. Concessions were necessary. We chose a simple categorization. A more sophisticated one might have been more rigorous but less practical for everyday practice. Thus, the “subepithelial cordectomy” class does not comprise any subdivision, such as “partial subepithelial cordectomy” and “total subepithelial cordectomy”. However, for cases of limited lesions where the remainder of the vocal fold epithelium is of normal appearance, resection of the entire epithelium could be excessive. That is why we avoided multiple types of subepithelial cordectomy and preferred stating that the epithelium *could* be resected and not that it *had* to be.

At a terminology level, we maintained the term “cordectomy” even for partial resections while in fact, according to etymology, the word “cordectomy” can only apply to a total resection of the vocal fold. We chose to keep “cordectomy” because it is the word most often used in the literature. We avoided the denomination “excisional biopsy” [1, 17] because the biopsy is tailored according to the lesion in order to resect the whole of the visible macroscopic lesion. It can therefore tally with a subepithelial cordectomy or with a more or less extensive transmuscular cordectomy.

The term “suspected lesion” encompasses the entire clinical modifications that affect the epithelium, and are referred to as “keratosis”, “hyperkeratosis”, “leukoplakia”, and “pachydermia”. Clinicians usually refer to the following nomenclature: “leukoplakia” for white plaques or patches; “erythroplasia” for red thickened epithelial patches; and “erythroleukoplakia” for mixed types of white and red epithelial modifications. “Pachydermia” is yet another clinical term used to describe larger areas that are affected by leukoplakia. All of these clinical terms are purely descriptive and do not establish a histological diagnosis [2, 8].

References

1. Blakeslee D, Vaughan CW, Shapshay SM, Simpson GT, Strong MS (1984) Excisional biopsy in the selective management of T1 glottic cancer: a three-year follow-up study. *Laryngoscope* 94:488–494
2. Crissman JD, Gnepp DR, Goodman ML, Hellquist H, Johns ME (1987) Preinvasive lesions of the upper aerodigestive tract: histologic definitions and clinical implications (a symposium). *Pathol Ann* 22:311–352
3. Czigler J, Savay L (1994) Primary CO₂ laser chordectomy in vocal cord carcinoma. *Laryngorhinootologie* 73:432–436
4. Davis RK (1997) Endoscopic surgical management of glottic laryngeal cancer. *Otolaryngol Clin North Am* 30:79–86
5. De Vincentiis M, Croce A, Gallo A, Primerano G, Ruoppolo G (1989) La cordectomie traditionnelle et au laser CO₂. Evaluation à long terme des résultats thérapeutiques. *Cah ORL* 24:431–437
6. Eckel HE, Thumfart WF (1992) Laser surgery for the treatment of larynx carcinomas: indications, techniques and preliminary results. *Ann Otol Rhinol Laryngol* 101:113–118
7. Eckel HE, Schneider C, Jungehülsing M, Damm M, Schröder U, Vössing M. (1998) Potential role of transoral laser surgery for larynx carcinoma. *Lasers Surg Med* 23:79–86
8. Friedman I, Ferlito A (1993) Precursors of squamous cell carcinoma. In: Ferlito A (ed) *Neoplasms of the larynx*. Churchill Livingstone, Edinburgh, pp 97–111
9. Kirschner JA (1984) Invasion of the framework by laryngeal cancer. Surgical and radiological implications. *Acta Otolaryngol (Stockh.)* 97:392–397
10. Kleinsasser O (1974) Microlaryngoscopy and endolaryngeal microsurgery. II. A review of 2500 cases. *HNO* 22:69–83
11. Krespi YP, Meltzer CJ (1989) Laser surgery for vocal cord carcinoma involving the anterior commissure. *Ann Otol Rhinol Laryngol* 98:105–109
12. Lillie JC, DeSanto LW (1973) Transoral surgery of early cordal carcinoma. *Trans Am Acad Ophthalmol Otolaryngol* 77:92–96
13. Lynch RC (1920) Intrinsic carcinoma of the larynx, with a second report of the cases operated on by suspension and dissection. *Trans Am Laryngol Assoc* 42:119–126
14. Mahieu HF, Patel P, Annyas AA, van der Laan T (1994) Carbon dioxide laser vaporization in early glottic carcinoma. *Arch Otolaryngol Head Neck Surg* 120:383–387
15. Mc Guirt WF, Koufman JA (1987) Endoscopic laser surgery. *Arch Otolaryngol Head Neck Surg* 113:501–505
16. Motta G, Esposito E, Cassiano B, Motta S (1997) T1-T2-T3 glottic tumors: fifteen years experience with CO₂ laser. *Acta Otolaryngol (Stockh)* 527:155–159
17. Peretti G, Cappiello J, Nicolai P, Smussi C, Antonelli A (1994) Endoscopic laser excisional biopsy for selected glottic carcinomas. *Laryngoscope* 104:1276–1279
18. Peretti G, Cappiello J, Berlucci M, Ansarin M, Antonelli AR (1997) Transoral CO₂ laser surgery for Tis, T1 and T2 glottic cancer. In: Kleinsasser O, Glanz H, Olofsson J (eds) *Advances in laryngology in Europe*. Elsevier Sciences, Amsterdam, pp 270–275
19. Piquet JJ, Chevalier D (1993) Laser et exérèse glottique. *Ann Otolaryngol Chir Cervicofac* 110:227–229
20. Remacle M, Lawson G, Jamart J, Minet M, Watelet JB, Delos M (1997) CO₂ laser in the diagnosis and treatment of early cancer of the vocal fold. *Eur Arch Otorhinolaryngol* 254:169–176
21. Rudert HH, Werner JA (1995) Endoscopic resections of glottic and supraglottic carcinomas with the CO₂ laser. *Eur Arch Otorhinolaryngol* 252:146–148
22. Steiner W (1993) Results of curative laser microsurgery of laryngeal carcinomas. *Am J Otolaryngol* 14:116–121
23. Steiner W, Ambrosch P (1996) Laser microsurgery for cancer of the larynx. *Minimum Invasive Ther Allied Technol* 5:159–164
24. Strong MS (1975) Laser excision of carcinoma of the larynx. *Laryngoscope* 85:1286–1289
25. Swarc BJ, Kashima HK (1997) Endoscopic management of a combined laryngocele. *Ann Otol Rhinol Laryngol* 106:556–559